



# Anaesthetic Management of a Neonate with Giant Cystic Hygroma

## Dev Kistik Higromalı Yenidoğan ve Anestezi Yönetimi

Emin Silay<sup>1</sup>, İsmail Coşkun<sup>1</sup>, Hüseyin Yıldız<sup>1</sup>, Vedat Bakan<sup>2</sup>, Halit Baykan<sup>3</sup>, Nimet Şenoğlu<sup>1</sup>, Hafize Öksüz<sup>1</sup>

<sup>1</sup>Department of Anaesthesiology and Reanimation, Faculty of Medicine, Kahramanmaraş Sütçü İmam University, Kahramanmaraş, Turkey

<sup>2</sup>Department of Paediatric Surgery, Faculty of Medicine, Kahramanmaraş Sütçü İmam University, Kahramanmaraş, Turkey

<sup>3</sup>Department of Plastic Surgery, Faculty of Medicine, Kahramanmaraş Sütçü İmam University, Kahramanmaraş, Turkey

Cystic hygroma, which originates from embryonic lymphoid tissue, is a benign tumour without any potential for malignancy. It is commonly located in the neck area. Anaesthetic management of a large neck mass may be challenging due to difficulty in intubation and the severe haemodynamic effects of surgical removal of a giant tumour. Serious consequences such as sudden airway occlusion resulting in hypoventilation and hypoxemia may arise. We present the anaesthetic management of a 15-day-old infant who underwent surgical removal of a cystic hygroma located on the left side of the neck. Anaesthesia was induced by mask ventilation with sevoflurane in 100% oxygen and intubation was carried out while maintaining spontaneous ventilation. The endotracheal tube was sutured to the tip of the right lip to avoid movement or extubation. In addition to arterial cannulation for invasive blood pressure monitoring, central venous catheterization for perioperative fluid management was put in place. After 6 hours of surgery, the infant was transported to the neonatal intensive care unit and was extubated without difficulty the next day. Facial nerve injury was observed to be temporary.

**Key Words:** Giant cystic hygroma, anaesthesia, newborn

Embriyonal lenfoid artıklardan köken alan kistik higroma, malign potansiyeli olmayan bir tümördür. Yerleşim itibarıyla genelde boyunda yer alır. Yenidoğan ve genç infantlarda boyunda geniş kitle nedeniyle hava yolu değişikliği gösterir, ayrıca kitle eksizyonu ciddi hemodinamik değişikliklere neden olabileceğinden anestezi yönetimi önem arz eder. Ani hava yolu tıkanması nedeniyle hypoventilasyon ve hipoksemi ile sonuçlanan ciddi problemlere neden olur. Boynunun sol tarafında dev kistik higromalı 15 günlük bebekte bu kitlenin eksizyonu için uygulanan anestezi yönetimini sunmayı amaçladık. Maske ile sevofluran indüksiyonu yapılan olgu spontan solunumu baskılanmadan entübe edildi, entübasyon tüpü yer değiştirmesin ve ekstübe olmasın diye ağız kenarına sütür ile tespit edildi, ayrıca invazif kan basıncı takibi için arter kanülasyonu uygulandı, 6 saatlik girişim sonrası yenidoğan yoğun bakım ünitesine alındı, problemsiz olarak ertesi gün ekstübe edildi. Ancak bebekte geçici sol yüz siniri hasarı görüldü.

**Anahtar Kelimeler:** Dev kistik higroma, anestezi, yenidoğan

## Introduction

Intubating a neonate with a giant lump on the neck is difficult. The anaesthesiologist must be ready to face various problems that may arise with respect to airway management in these patients. Even an anatomically normal respiratory tract is susceptible to upper airway obstruction, and respiratory distress can easily develop. Muscle composition, structure of the thorax, functional residual capacity and oxygen consumption must be taken into consideration, especially in newborn and young infants who have more limited reserves. Thus, airway management of a newborn infant with a giant cervical lump may be an exceedingly difficult task. In addition, haemodynamic alterations following excision of a giant lump may lead to serious problems in a neonate.

## Case Report

A term neonate was referred to the Department of Paediatric Surgery because of a giant mass in the left cervical region after delivery via Caesarean section. The left cervical lump was observed during the 27<sup>th</sup> week prenatal ultrasonography of the infant's 32-year-old mother. The possible diagnosis was established as cystic hygroma after ultrasonography and magnetic resonance imaging. An anaesthesiology consent form had been obtained from the parents of the patient. And also a consent for scientific publication of patient's medical informations and photographs from parents had been obtained. Surgical excision of the lump was scheduled for treatment (Figure 1).

The anaesthesiologist observed a lump in the left cervical region that extended to the base of mouth in the preoperative examination. The neck of the patient was in a hyperextended position due to its large size (13x15x13 cm). The baby was breathing and sucking without any problem and weighed 3550 g (Figure 2).

Before transfer to the operating room a 27 G cannula was inserted through a peripheral vein, and iv fluids were started. Standard monitoring consisting of ECG, non-invasive blood pressure and pulse oximetry was used intraoperatively. Neck extension was not easy because of

**Address for Correspondence/Yazışma Adresi:** Dr. Emin Silay, Department of Anaesthesiology and Reanimation, Faculty of Medicine, Kahramanmaraş Sütçü İmam University, Kahramanmaraş, Turkey Phone: +90 344 221 14 31 E-mail: eminsilay@hotmail.com

©Telif Hakkı 2013 Türk Anesteziyoloji ve Reanimasyon Derneği - Makale metnine www.jtaics.org web sayfasından ulaşılabilir.

©Copyright 2013 by Turkish Anaesthesiology and Intensive Care Society - Available online at www.jtaics.org

Received / Geliş Tarihi : 08.05.2012

Accepted / Kabul Tarihi: 19.07.2012

Available Online Date /

Çevrimiçi Yayın Tarihi : 08.04.2013

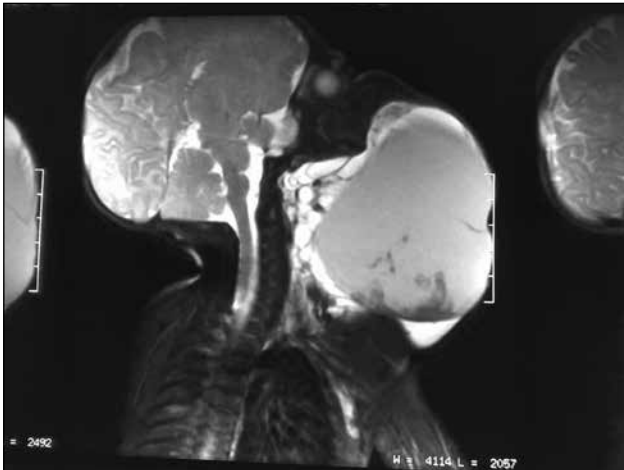


Figure 1. The magnetic resonance image of the lump

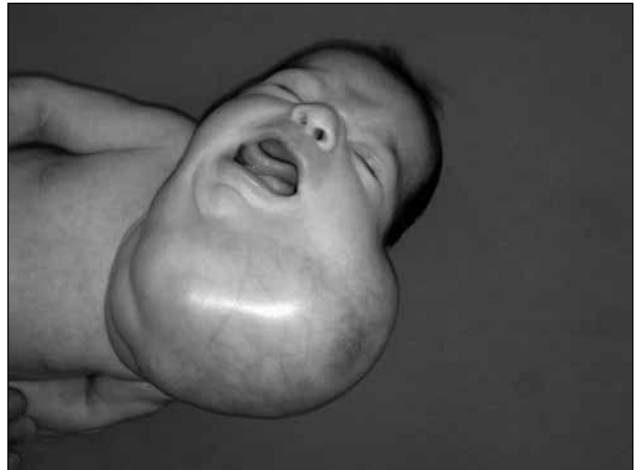

Figure 2. The image of patient in preoperative period

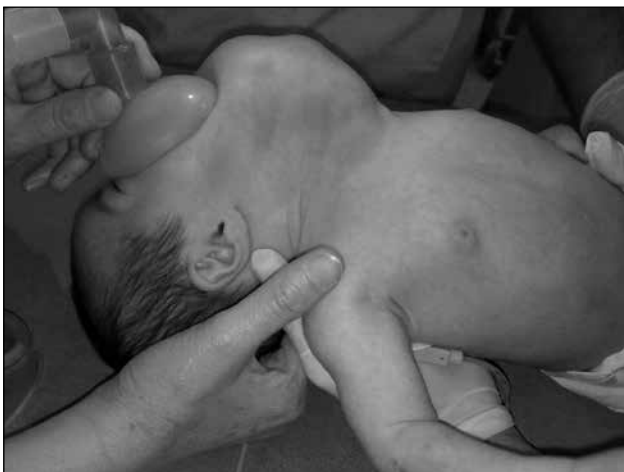

Figure 3. Ventilation with mask

the mass, and intubation was performed by two anaesthesiologists, one of them helping positioning by lifting the neck. Five percent sevoflurane in 100% oxygen was applied through a facemask, while the baby was breathing spontaneously (Figure 3). Laryngoscopy was difficult because the mass was pushing the tongue up from the floor of the mouth.

The epiglottis could only be visualized using a size 0 Macintosh Blade and intubation was performed with a cuffed, size 3 endotracheal tube. The location of the tube was verified with auscultation of each hemithorax. The tube was sutured to the lips in order to prevent its dislocation. Rocuronium 2 mg was given, and anaesthesia was maintained with 2-3% sevoflurane. Doses of 0.5 mg rocuronium were repeated if needed. For prevention of upper airway oedema, 5 mg methylprednisolone was given intravenously. Due to the large surgical excision, and the anatomical location of large adjacent vessels, haemodynamic monitoring and treatment of blood and fluid loss were important in this case. For this reason, invasive arterial blood pressure monitoring was instituted using a brachial artery cannula, and a central venous catheter was inserted through the femoral vein. A urinary catheter was placed to monitor urine output, and a rectal temperature probe was inserted. Surgery lasted 6 hours, and the observed vital signs were within the following ranges: systolic blood pressure 52-72 mm Hg, diastolic blood pressure 28-34 mm Hg, pulse rate 106-145 beats per minute and end-tidal

carbon dioxide tension 34-40 mm Hg. Body temperature ranged between 36.3 and 37.2°C and SpO<sub>2</sub> between 97 and 99%.

During the operation, Lactated Ringer's solution at a rate of 9 mL h<sup>-1</sup> and dextrose solution at 15 mL h<sup>-1</sup> were given in a 1:3 ratio. To counter blood loss, 50 mL of erythrocyte suspension was transfused. Urine output was 30 mL. At the end of the operation, the patient was transferred to the neonatal intensive care unit. For the treatment of upper airway oedema, 1 mg dexamethasone was given. The patient was extubated on the second postoperative day. No problems were encountered in the airways after extubation, but left facial nerve injury was observed. The patient was discharged on the 24<sup>th</sup> postoperative day. Healing of the facial nerve injury was observed at the 2-month follow-up visit.

## Discussion

Cystic hygroma is a congenital, developmental malformation originating from the lymphatic vascular system and has no malignant potential. It can arise anywhere within the body; however, 70-80% of cases are located in the neck, particularly in the left posterior cervical triangle (1). Treatment choices include continued observation, repetitive suction, injection of curing agent into the mass, radiation therapy and radio frequency treatment (2, 3). However, the only radical treatment method is surgical removal. General surgery is performed when the patient is 18 months to 2 years old (4). In this case, the size of the lump was exceptionally large and it was likely to cause respiratory distress or swallowing difficulties; it was thus considered for immediate surgical removal (4, 5). As a difficult airway was predicted in this case, anaesthesia was induced by inhalation during spontaneous breathing, and endotracheal intubation was performed. Furthermore, the surgical team was ready to aspirate the fluid within the lump to facilitate airway management (4).

Given the difficult surgical dissection and large surgical field, another possible problem was displacement of the endotracheal tube out of or further down the vocal cords or into the bronchus, even by simple flexion or extension of the cervical vertebra (6, 7). In order to prevent displacement, the tube was sutured to the lips after verifying the location of the tube with auscultation of each hemithorax. Extubation time is also very important at the end of the operation. It is known that paralysis of the 7<sup>th</sup>, 11<sup>th</sup> and 12<sup>th</sup> cranial nerves occurs in 20% of patients undergoing cystic hygroma removal (3). This paralysis occurs due to traction of the nerves during surgery and is

generally reversible (7). In this case, the patient was extubated on the second postoperative day with no adverse events, although the neonatal intensive care team was ready for reintubation. Left facial nerve paralysis, which healed in the second postoperative month, was observed. The patient was discharged on the 24<sup>th</sup> postoperative day.

## Conclusion

In this case report, we have described the anaesthetic management of a newborn with a cervical tumour. Intubating the patient without stopping spontaneous breathing, and suturing the endotracheal tube to keep it in place were crucial aspects of the anaesthetic care. Haemodynamic monitoring for effective treatment of probable blood loss and preventing hypothermia are critical factors in anaesthetic management. We believe that the decision to extubate should not be taken in a short time.

## Conflict of Interest

No conflict of interest was declared by the authors.

**Peer-review:** Externally peer-reviewed.

**Informed Consent:** Written informed consent was obtained from patients who participated in this case.

## Author Contributions

Concept - E.S., İ.C.; Design - E.S., H.Y., H.B.; Supervision - E.S., V.B.; Funding - E.S., İ.C., H.Y.; Materials - E.S., V.B., H.B., H.Ö.; Data Collection and/or Processing - E.S., İ.C., V.B., H.Y., N.Ş., H.Ö.; Analysis and/or Interpretation - E.S., İ.C.; Literature Review - E.S., İ.C., H.Y., V.B., H.B., N.Ş.; Writer - E.S.; Critical Review - E.S., İ.C., H.Y.

## Çıkar Çatışması

Yazarlar herhangi bir çıkar çatışması bildirmemişlerdir.

**Hakem değerlendirmesi:** Dış bağımsız.

**Hasta Onamı:** Yazılı hasta onamı bu olguya katılan hastalardan alınmıştır.

## Yazar Katkıları

Fikir - E.S., İ.C.; Tasarım - E.S., H.Y., H.B.; Denetleme - E.S., V.B.; Kaynaklar - E.S., İ.C., H.Y.; Malzemeler - E.S., V.B., H.B., H.Ö.; Veri toplama ve/veya işlemesi - E.S., İ.C., V.B., H.Y., N.Ş., H.Ö.; Analiz ve/veya yorum - E.S., İ.C.; Literatür taraması - E.S., İ.C., H.Y., V.B., H.B., N.Ş.; Yazı yazan - E.S.; Eleştirel inceleme - E.S., İ.C., H.Y.

## References

1. Wang TC, Wu CM, Sun LS, Chiang TC. [Giant cystic hygroma: a case report]. Zhonghua Yi Xue Za Zhi (Taipei) 1993; 51: 479-81.
2. Samuel M, McCarthy L, Boddy SA. Efficacy and safety of OK-432 sclerotherapy for giant cystic hygroma in a newborn. Fetal Diagn Ther 2000; 15: 93-6. [CrossRef]
3. Gross E, Sichel JY. Congenital neck lesions. Surg Clin North Am 2006; 86: 383-92. [CrossRef]
4. Sharma S, Aminuldin AG, Azlan W. Cystic hygroma: anaesthetic considerations and review. Singapore Med J 1994; 35: 529-31.
5. Ishaq M, Minhas MR, Hamid M, Punjwani R. Management of compromised airway due to unusual presentation of cystic hygroma. J Pak Med Assoc 2006; 56: 135-7.
6. Griscom NT, Wohl ME. Dimensions of the growing trachea related to age and gender. AJR Am J Roentgenol 1986; 146: 233-7. [CrossRef]
7. Kim H, Kim HS, Oh JT, Lee JR. Anesthetic management for neonate with giant cystic hygroma involved upper airway -A case report-. Korean J Anesthesiol 2011; 60: 209-13. [CrossRef]

## Etkinlik Takvimi

3-6 Ekim 2013	Ulusal Rejyonel Anestezi Kongresi	Sheraton İstanbul Maslak Hotel	www.radkon2013.org
5-9 Ekim 2013	26 <sup>th</sup> ESICM Annual Congress	Palais De Congress Paris, France	www.esicm.org
31 Ekim-2 Kasım 2013	Singapore Society of Anaesthesiologists 18 <sup>th</sup> Asean Congress of Anaesthesiologists	Suntec City, Singapore	www.anaesthesia.org.sg
20-24 Kasım 2013	Türk Anesteziyoloji ve Reanimasyon Derneği 47. Ulusal Kongresi	Rixos Sungate Otel, Antalya	www.tard.org.tr
5-7 Aralık 2013	2 <sup>nd</sup> European Airway Congress	Harbiye Military Museum and Cultural Center, İstanbul	www.eamsonline.org
23-27 Nisan 2014	17. Ulusal Yoğun Bakım Kongresi	Belek, Antalya	www.yogunbakim.org.tr
8-11 Mayıs 2014	Asian Society of Paediatric Anaesthesiologist 12 <sup>th</sup> ASPA Congress	İstanbul	www.tard.org.tr

Değerli okuyucularımız, ilgi alanlarımız ile ilgili ulusal ve uluslararası toplantıları sayfalarımızdan duyuracağız. Duyurulmasını istediğiniz etkinlikleri bize bildirebilirsiniz.