



An editorial comment on this article is available at page 127.

Importance of Sonography for Guiding Central Venous Cannulation in Patients with Neurofibromatosis

Nörofibromatoz Hastalarında Santral Venöz Kanülasyona Rehberlikte Sonografinin Önemi

V.K. Mohan, Neisevilie Nisa

All India Institute of Medical Sciences, New Delhi, India

A 15-year-old boy with neurofibromatosis type 1 (NF1) was referred to us for central venous catheter insertion, and on ultrasound of the neck, he was found to have extensive involvement of the brachial plexus due to the nerve sheath tumour. Multiple hypoechoic lesions resembling the internal jugular vein and internal carotid artery were visualised and could be differentiated from the vessels by Doppler ultrasound. The importance of analyzing sonographic images of nerve sheath tumours, which can mimic blood vessels, and the importance of Doppler ultrasound for guiding central venous catheters in such patients to avoid nerve injury are discussed in this case report.

Keywords: Neurofibromatosis, ultrasound, central venous cannulation

Nörofibromatoz tip 1 olan 15 yaşında bir erkek hasta santral venöz kateter takılması için bize yönlendirildi. Hastanın boyun ultrasonunda sinir kılıfı tümöründen dolayı yaygın brakial plexus tutulumu izlendi. İnternal juguler ven ve internal karotis arteri anımsatan çoklu hipoekojen lezyonlar görüldü ve Doppler ultrason ile damarlardan ayırt edilebildi. Bu vaka sunumunda, kan damarlarını taklit edebilen sinir kılıfı tümörlerinin sonografik görüntülerinin önemi ve bu hastalarda sinir hasarlarından kaçınmak için santral venöz kateterlerine rehberlik etmesi açısından Doppler ultrasonun önemi tartışılmaktadır.

Anahtar Sözcükler: Nörofibromatoz, ultrason, santral venöz kanülasyon

Introduction

Neurofibromatosis type 1 (NF1) involves the peripheral nerves with an incidence of 1:2500–3300; however, the involvement of the brachial plexus (BP) is rare (1). It can cause wide distortion of the underlying BP anatomy, and central venous cannulation (CVC) can be challenging because of the risk involved in causing permanent nerve injury. In many developing countries, ultrasound (US) is not freely available and central venous catheter insertion is commonly performed using the traditional landmark technique.

We report a case of a patient who required CVC and had extensive involvement of BP caused by the nerve sheath tumour, which resembled the internal jugular vein and external carotid artery, as observed on US of the neck. We discuss the importance and role of sonography for guiding CVC in patients with NF to avoid nerve injury.

Case Presentation

A 15-year-old boy with NF1 had neuropathic pain along the supply of the right ulnar nerve for the past 3 years and was referred to us for CVC because of difficult peripheral venous access. He was on oral non-steroidal anti-inflammatory drugs (NSAIDs) and had received 1 session of pulse radio frequency ablation a month previously for the neuropathic pain. After explaining the procedure, written consent was obtained and the patient was positioned for right internal jugular vein cannulation. Standard monitors for American Society of Anesthesiology grade 1 were attached and supplementary oxygen was given via a nasal prong with a flow of 3 L min⁻¹. Intravenous fentanyl bolus of 0.5 µg kg⁻¹ was given for sedation. An initial US scan was performed with the middle of the probe along the apex of the triangle formed by the 2 heads of sternocleidomastoid muscles and clavicle using SonoSite 180 plus and a linear array 6–13 MHz probe (SonoSite Drive SE Bothell, WA, USA). Multiple vascular-like structures having the same diameter of the internal jugular vein and external carotid artery were visualised (Figures 1 and 2). Initially, they were thought to be some anatomical variants and branches of the internal jugular vein, but on applying pressure, they were not compressible. The internal carotid artery could not be differentiated from these structures because the usual arterial pulsation was not evident in this case. On tracing the structures cranially and caudally, similar vascular-like structures were seen, and only on colour Doppler US,

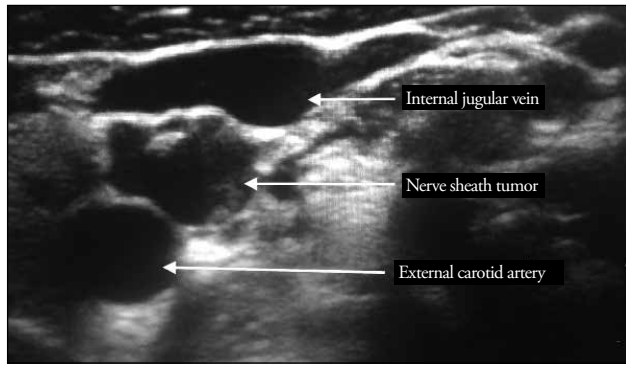


Figure 1. Multiple non-compressible vascular-like structures seen around the internal jugular vein and external carotid artery

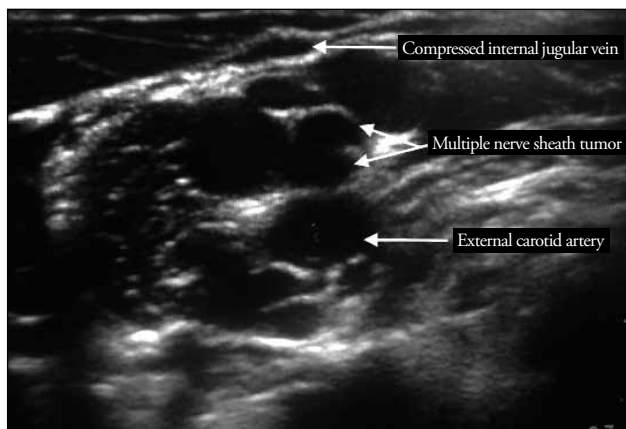


Figure 2. Nerve sheath tumours appearing as vascular structures between the internal jugular vein and external carotid artery

the internal jugular vein and external carotid artery could be delineated from the neural tissue, which has extensively involved the BP.

The skin and subcutaneous tissues were anaesthetised with 2% lidocaine using a 25-gauge needle. After skin anaesthesia, a 16-gauge, 10-cm-long needle was introduced in an out-of-plane technique. The tip of the needle was advanced under direct visualisation without piercing the nerve until it punctured the internal jugular vein and negative aspiration confirmed free flow of blood. A 7-Fr triple lumen catheter (Certrofix, B.Braun Melsungen AG, Germany) was successfully placed using the Seldinger technique. All ports were aspirated and flushed with heparinised saline, and the triple lumen catheter was secured.

During the procedure, the patient had no discomfort, pain or any sign of the needle piercing the neural tissues. The right internal jugular vein was successfully cannulated under US guidance without nerve injury. An US scan on the other side of neck showed a similar sonographic image of BP involvement. An US scan of the bilateral groin area showed a normal anatomical relation between the vascular structures and femoral nerve.

Discussion

Neurofibromatosis type 1 is an autosomal dominant disease, with NF1 being the most common disease that affects a wide range of physiological systems (2). NF1 presents with neuro-cutaneous symptoms such as café au lait spots (95%) and axillary freckles (75%) (1), which were evident in our case. Reynolds et al. (3) have described the sonographic appearance of nerve sheath tumours as a hypoechoic mass with an echogenic ring and posterior acoustic enhancement (4), and Beggs et al. (5) have described the nerve running into the tumour as a pathognomonic feature of nerve sheath tumours. These sonographic features of nerve sheath tumours can resemble those of vascular structures, and these tumours can therefore be mistaken for vessels during CVC. In our case, the carotid artery also appeared hypoechoic with a hyperechoic ring and it was non-compressible. US alone could not differentiate it from neural tissues, and it was clearly differentiated only on colour Doppler US. This shows that high-cost scanners with colour Doppler US facility should be used in patients with NF because differentiating between vascular structures and nerve tissues can be difficult. Other methods that can be used to differentiate between these are dynamic compression of the probe over the skin surface that can easily compress the vein and the arterial pulsation (although it was not evident in our case) can help differentiate vascular structures from neural tissues.

Although the internal jugular vein was successfully cannulated under US guidance in our case, the sonographic image showed that there is a high risk of nerve injury during CVC in NF patients involving BP. The large needle size used can cause permanent injury to the nerve; therefore, Doppler US is highly recommended in these patients for CVC.

Conclusion

We emphasise the importance of central venous catheter insertion in patients with NF under sonographic guidance to avoid nerve injury. In centres where US is routinely not available, femoral vein cannulation can be considered. Cutaneous markers such as café au lait spots and axillary freckles can be used as clinical markers for detecting possible underlying nerve sheath tumours, which can involve BP, when considering CVC.

Informed Consent: Written informed consent was obtained from patient who participated in this case.

Peer-review: Externally peer-reviewed.

Author Contributions: Concept – N.N.; Design – N.N., V.K.M.; Supervision – N.N., V.K.M.; Data Collection and/or Processing – N.N., V.K.M.; Analysis and/or Interpretation – N.N., V.K.M.; Literature Search – N.N., V.K.M.; Writing Manuscript – N.N.; Critical Review – N.N., V.K.M.

Conflict of Interest: No conflict of interest was declared by the authors.

Financial Disclosure: The authors declared that this study has received no financial support.

Hasta Onamı: Yazılı hasta onamı bu olguya katılan hastadan alınmıştır.

Hakem Değerlendirmesi: Dış bağımsız.

Yazar Katkıları: Fikir – N.N.; Tasarım – N.N., V.K.M.; Denetleme – N.N., V.K.M.; Veri Toplanması ve/veya İşlemesi – N.N., V.K.M.; Analiz ve/veya Yorum – N.N., V.K.M.; Literatür Taraması – N.N., V.K.M.; Yazıyı Yazan – N.N.; Eleştirel İnceleme – N.N., V.K.M.

Çıkar Çatışması: Yazarlar çıkar çatışması bildirmemişlerdir.

Finansal Destek: Yazarlar bu çalışma için finansal destek almadıklarını beyan etmişlerdir.

References

1. Binder DK, Smith JS, Barbaro NM. Primary brachial plexus tumors: Imaging, surgical, and pathological findings in 25 patients. *Neurosurg Focus* 2004; 16: E11.
2. Hirsch NP, Murphy A, Radcliffe JJ. Neurofibromatosis: clinical presentations and anaesthetic implications. *Br J Anaesth* 2001; 86: 555-64. [\[CrossRef\]](#)
3. Reynolds DL, Jacobson JA, Inampudi P, Jamadar DA, Ebrahim FS, Hayes CW. Sonographic characteristics of peripheral nerve sheath tumors. *AJR Am J Roentgenol* 2004; 182: 741-4. [\[CrossRef\]](#)
4. Kara M, Yilmaz A, Ozel S. Sonographic imaging of the peripheral nerves in a patient with neurofibromatosis type 1. *Muscle Nerve* 2010; 41: 887-8. [\[CrossRef\]](#)
5. Beggs I. Sonographic appearances of nerve tumors. *J Clin Ultrasound* 1999; 27: 363-8. [\[CrossRef\]](#)